

Polish Society of Perinatal Medicine

ARCHIVES of PERINATAL MEDICINE

Editor

Grzegorz H. Bręborowicz



QUARTERLY

Volume 19(1)

2013

ISSN 1505-0580

Index Copernicus 5.63

Scientific Publishers OWN

ARCHIVES OF PERINATAL MEDICINE Vol. 19(1), 2013
Official Journal of the Polish Society of Perinatal Medicine

Editor-in-Chief

GRZEGORZ H. BRĘBOROWICZ

Polish Society of Perinatal Medicine

Polna 33, 60-535 Poznań, Poland

tel.: (+ 48-61) 8419283

fax: (+ 48-61) 8419204

e-mail: gbrebor@gpsk.am.poznan.pl

<http://www.ptmp.pl>

Copyright ©

by Polish Society of Perinatal Medicine

Poznań 2013

All rights reserved

ISSN 1505-0580

Published by

Ośrodek Wydawnictw Naukowych

Scientific Publishers OWN

Institute of Bioorganic Chemistry

Polish Academy of Sciences

Wieniawskiego 17/19, 61-713 Poznań, Poland

tel.: (+ 48-61) 8528503

fax: (+ 48-61) 8520671

e-mail: wojtow@man.poznan.pl

Technical Editor

ANDRZEJ WÓJTOWICZ

Printed in Poland (Moś i Łuczak, Poznań)

Congenital Letterer-Siwe disease

ANDREI PLOTSKI¹, ELENA LUPACHIK², VASILY KONONOV²,
SVETLANA SEMENSOVA³, ELENA SMIRNOVA³

Abstract

Langerhans' cells histiocytosis represent a group of rare disorders characterized by reactive infiltrates that usually are composed of varying proportions of histiocytes, lymphocytes, plasma cells, eosinophils, and neutrophils. Letterer-Siwe disease is the most severe form of histiocytoses. It commonly presents within the first year of life and, occasionally, in neonates. We present clinical and histopathological pictures in a neonate with unrecognized congenital Letterer-Siwe disease. The child died due to diffuse infiltration of lungs with histiocytic cells.

Key words: histiocytosis, congenital, pregnancy

Introduction

Langerhans' cells histiocytosis (LCH) is rare disease in which an uncontrolled proliferation of Langerhans' cells occurs in one or more body systems or tissues, leading to different clinical manifestation [1]. Langerhans' cells histiocytosis nowadays includes diseases previously designated as histiocytosis X, namely eosinophilic granuloma, Hand-Schüller-Christian syndrome and Letterer-Siwe disease with the similar morphological structure of lesions. That's why the term Langerhans' cell histiocytosis is more preferable than term histiocytosis X [2, 3].

Letterer in 1924 and Siwe in 1933 described a severe disease in children with nonspecific systemic signs and symptoms of fever, weight loss, lethargy, rash, anemia, thrombocytopenia, hepatosplenomegaly and lymphadenopathy. Letterer-Siwe disease in most cases usually seen in infants during the first and second years of life. Congenital form of disease is uncommon [4, 5]. It can be either fatal in intrauterine life or within a few weeks of birth. We report on an infant who died within 3 days due to diffuse infiltration mainly of lungs with Langerhans histiocytic cells.

Case report

A 37-weeks gestation male was born by normal vaginal delivery to a 20-year-old mother 14.09.2009. The course of pregnancy was usual. The Apgar scores of baby at birth were 8 and 8, weight was 3140 g, length of body – 51 cm. The general condition of infant is regarded as severe. The infant presented with multiple vesi-

culated and pustulated crusting skin lesions (Fig. 1), some of them was bleeding. Also we observed hemorrhages in the mouth. Breathing was weakened on both sides with crepitation. The liver and spleen were not enlarged. Respiratory rate was 56 per minute, pH 7.29, pCO₂ 47, pO₂ 42. A chest X-ray at birth revealed diffuse infiltrates in both lungs. Congenital infection was suspected (streptoderma? listeriosis?) and the infant was started on antibiotics. The baby first improved on oxygen therapy. But respiratory insufficiency increased, hemodynamic instability was noted and mechanical ventilation was started. Blood and urine cultures were all negative. Evaluation for cytomegalovirus, syphilis, herpes simplex virus, toxoplasma, rubella and hepatitis was negative. It was noting the original skin lesions were healing while new lesions were seen and had tendency to fuse. The patient died on the third day from progressive respiratory failure.

Autopsy revealed histiocytic cells extensively infiltrating the lungs, thymus, mesenteric lymph nodes, pancreas (Fig. 2-5) and dermis. In lungs the infiltrates of histiocytic cells were located around small bronchi and bronchioles.

Discussion

Incidence of Langerhans' cell histiocytosis is 0,2-1 per 100 000 children under the age 15 years. The exact etiology of LCH still is unknown. Langerhans' cells belong to the normal human cellular environment and their transformation to a pathologic growth pattern remains unclear [3].

¹ Grodno State Medical University, Grodno, Belarus

² Grodno Regional Pathology Department, Grodno, Belarus

³ Grodno Clinical Emergency Hospital, Grodno, Belarus

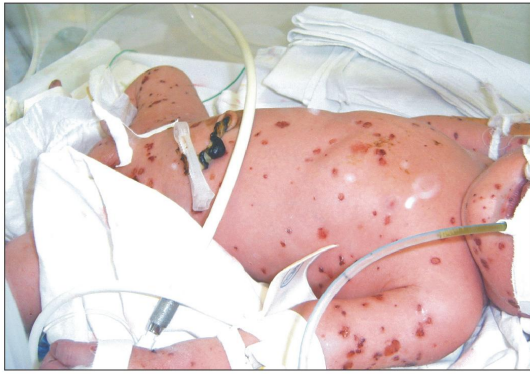

Fig. 1. Multiple vesiculated and pustulated crusting skin rash

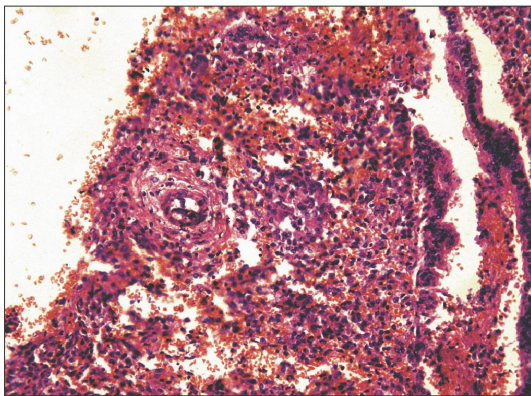


Fig. 2. Lung infiltrated by histiocytes; staining with hematoxylin and eosine, $\times 200$

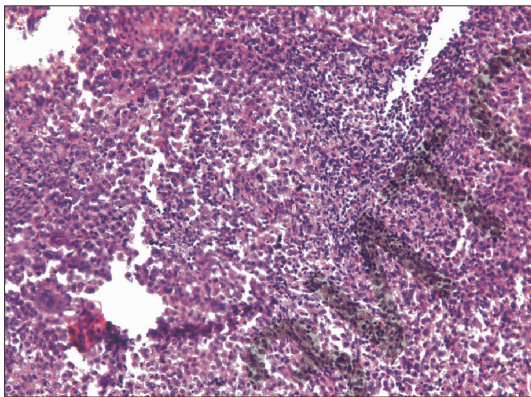


Fig. 3. Partially infiltrated tissue of thymus; staining with hematoxylin and eosine, $\times 200$

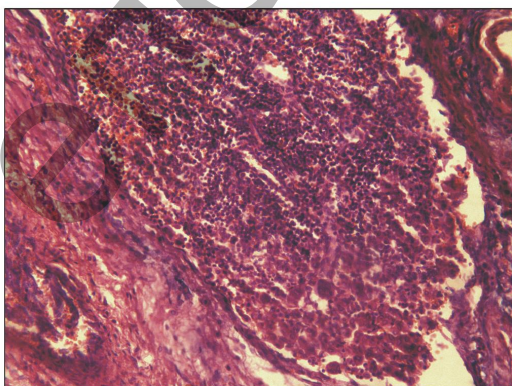


Fig. 4. Mesenteric lymph nodus infiltrated by histiocytes; staining with hematoxylin and eosine, $\times 200$

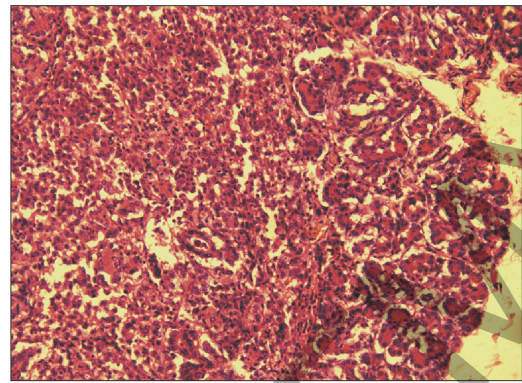


Fig. 5. Histiocytes in pancreas; staining with hematoxylin and eosine, $\times 200$

The Langerhans' cell was named after Paul Langerhans who identified it as a dendritic cell of the epidermis previously of uncertain origin and function [2]. He initially supposed these cells represented the end parts of nerve cells. Later studies showed that Langerhans' cells belong to a specific subset of macrophages termed dendritic cells or antigen-presenting cells. Normally, these cells are located in the epidermis, the epithelium of the mucous membrane of the mouth, esophagus, respiratory tract, vagina, and cervix. Langerhans' cells have been seen in the epidermis of 1st trimester embryo [6]. Dendritic cells are antigen-sensing and uptake cells that become activated and migrate to lymph nodes where they stimulate lymphocytes to perform immune functions. Langerhans' cells express CD1 and S-100 protein. In 1961 Birbeck discovered by electron microscopy that Langerhans' cells contained unique granules that are now referred to as Birbeck granules. The exact function of the granules remains unclear [7].

It was identified clonal proliferation of Langerhans' cells and supposed a neoplastic disorder arising from mutations of bone marrow precursor cells [8]. Immune disregulation and viral infection were discussed but not confirmed up to now. Viruses have been suggested to be a cause of Langerhans' cell histiocytosis – a case of Letterer-Siwe disease was described in a term stillborn boy whose mother received polio vaccine and Asiatic flu vaccine during pregnancy [9]. This case raises possibility of viral etiology of Langerhans' cell histiocytosis.

Clinical manifestation depends on degree of distribution proliferating cells in organism. Letterer-Siwe disease usually presents with fever, weight loss, hepatosplenomegaly, lymphadenopathy and extensive skin rash in combination with anemia, neutropenia and thrombocytopenia. Rash may be scaly, seborrheic, eczematoid, and sometimes purpuric in any part of body [1]. The clinical presentation of acute congenital histiocytosis may

also include bleeding per rectum or protein losing enteropathy when the gastrointestinal tract is involved – but these symptoms were not seen in our patient.

The basis of diagnosis is to find aggregates of Langerhans' histiocytosis cells. These cells are small to medium-sized and have pale convoluted nuclei in hematoxylin and eosin-stained sections. The cytoplasm is pale pink and cytoplasmic borders are poorly defined. In most cases Langerhans' histiocytosis cells associated with various types of inflammatory cells, most notably eosinophils, but also lymphocytes, plasma cells and polymorphonuclear leucocytes. The number of inflammatory cells is highly variable. Original tissue of the affected organ may be completely replaced by diffuse growths of Langerhans cells and pathologist even doubt what organ he examine. Of course, immunohistochemical and ultrastructural identification of Langerhans' histiocytosis cells has contributed to the diagnosis of this disease. By electron microscopy, aggregates of Langerhans' histiocytosis cells are easily recognized by their highly convoluted nuclei. The cytoplasm of Langerhans' histiocytosis cells contain unique rod- and racquet-shaped granules (Birbeck granules). But in our case we had no possibility to perform these investigations.

Prognosis for severe Letterer-Siwe disease is unfavorable with mortality greater than 65%. Attempts to connect prognosis with the structure of pathomorphological lesions were unsuccessful. The process also can be selflimiting (so called Hashimoto-Pritzker disease), but most of the benign congenital histiocytosis reported in the literature demonstrated only solitary skin involvement without impairment of the lungs [1, 10, 11].

Our patient demonstrated typical clinical signs of histiocytosis, but it was assessed like congenital infection. It's the most widespread mistake due to rare occurrence of this condition.

There's also no evidence for hereditary cause. By the way the woman had successful pregnancy in 2011 without any problems in female infant.

Conclusion

Langerhans' cell histiocytosis involving multiple organs is a rare disease that causes rapid mortality in intrauterine and neonatal life. The diagnosis of Letterer-Siwe

disease should be considered in a neonate with vesiculated crusting skin lesions and no effect from antibiotic therapy.

References

- [1] Arceci R.J., Weinstein H.J. (2005) *Neoplasia*. [In:] MacDonald M.G., Seshia M.M.K., Mullet M.D. *Avery's Neonatology: Pathophysiology and management of the newborn*. Lippincott Williams & Wilkins, Philadelphia.
- [2] Hammar S.P., Allen T.C. (2008) *Histiocytosis and storage diseases*. In: Tomaszefski J.F., Cagle P.T., Farver C.F., Fraire A.E. *Dail and Hammar's Pulmonary Pathology*. Springer Science+Business Media, LLC, New York.
- [3] Olschewski T., Micke O., Seegenschmiedt M.H. (2008) *Langerhans' Cell Histiocytosis*. [In:] Seegenschmiedt M.S., Makoski H.-B., Trott K.-R. Brady L.W. *Radiotherapy for Non-Malignant Disorders*. Springer Berlin Heidelberg, New York.
- [4] Pant C., Madonia P., Bahna S.L. et al. (2009) *Langerhans cell histiocytosis, a case of Letterer Siwe disease*. J. La. State Med. Soc. 161(4): 211-2.
- [5] Vade A., Hayani A., Pierce K.L. (1993) *Congenital histiocytosis X* *Pediatr. Radiol.* 23:181-2.
- [6] Breathnach A.S., Wyllie L.M. (1965) *Electron microscopy of melanocytes and Langerhans cells in human fetal epidermis at fourteen weeks*. J. Invest. Dermatol. 44: 51-60.
- [7] Aleotti A., Cervelatti F., Bovolenta M.R. et al. (1998) *Birbeck granules: contribution to the comprehension of intracytoplasmic evolution*. J. Submicrosc. Cytol. Pathol. 30(2): 295-8.
- [8] Willman C.L., Busque L., Griffith B.B., Favara B.E. et al. (1994) *Langerhans' cell histiocytosis (histiocytosis X) – a clonal proliferative disease*. N. Engl. J. Med. 331(3): 154-60.
- [9] Anquist G., Holyoke J.B. (1960) *Congenital Letterer-Siwe disease (reticuloendotheliosis) in a term stillborn infant*. J. Pediatr. 57: 897-904.
- [10] Pavlović M.D., Minić F., Zolotarevski L. et al. (2006) *Disseminated crusted papules in a newborn*. Vojnosanit. Pregl. 63(7): 681-3.
- [11] Morgan K.W., Callen J.P. (2001) *Self-healing congenital Langerhans cell histiocytosis presenting as neonatal papulovesicular eruption*. J. Cutan. Med. Surg. 5(6): 486-9.

✉ Andrei Plotski
Grodno State Medical University
Grodno, Gorky street 80, Belarus