

CARDIOPATHIC AMYLOIDOSIS AS A PATHOGENETICAL FACTOR FOR DEVELOPMENT OF MYOCARDIAL INFARCTION AT FAMILIAL MEDITERRANEAN FEVER

S.V. Hambardzumyan

Yerevan State Medical University after M.Heratsi, Armenia

Familial Mediterranean fever is characterized by recurrent fever, peritonitis, pleuritis, pericarditis, skin lesions and arthritis. Clinical-morphological analysis of 68 autopsy cases was done. Cardiac amyloidosis in FMF leads to heart failure. Macroscopically cardiomegaly was observed. The morphological manifestations of cardiac affection in FMF were amyloidosis of the vessels and myocardium stroma. Cardiac failure can develop before renal amyloidosis and uremia.

Myocardium infarction develops in background of cardiac lesions in FMF, in which amyloid angiopathias and coronary vasculitis are main predisposing pathogenic factors.

Homozygotes for M694V may experience more severe disease and may be more likely to develop amyloidosis.

Key words: *Familial Mediterranean fever, cardiopathic amyloidosis, morphology, myocardial infarction.*

Introduction

Familial Mediterranean fever (FMF) is characterized by recurrent fever, peritonitis, pleuritis, pericarditis, skin lesions, arthritis and often is complicated with systemic amyloidosis [6]. Renal involvement is known as the main complication in FMF, mostly presents with nephrotic syndrome and chronic renal failure [3, 5]. The cardiac and lung affections are known as relatively rare complications in FMF, often without clinical manifestations, or manifested after renal transplantation [4, 7].

The purpose of the present study is to characterize the morphological features of cardiac lesions in patients with FMF dead from complications, and to evaluate thanatogenesial peculiarities of disease with cardiac involvement.

Material and methods

We have investigated morphologically the autopsy material from 68 patients aged 15-65 years and dead from complications of FMF without renal transplantation. The retrospective investigation of clinical and instrumental data of those patients was done.

The investigated material was classified to the clinical forms and stages of FMF, according to the patient's age and period of manifestation of the disease, genetic investigation results.

The pathological changes in all organ-systems were evaluated macro- and microscopically in cadaver dissection. Fragments from organs were taken for preparation of paraffin sections. For histological investigation were used hematoxylin and eosin, methyl violet, Congo red, followed by polarization microscopy, thioflavin T staining methods. For immunohistochemical investigation monoclonal antibodies against amyloid-A were used (Sigma Aldrich, Germany).

Results and discussion

Cardiac affections clinically and morphologically manifested in FMF were evaluated (Tab. 1).

Table 1 – Clinical and morphological manifestations of cardiac lesions in FMF in autopsy material

Cardiac lesions in FMF	Amount of autopsy cases
Clinically manifested only	2
Morphologically manifested only	9
Clinically and morphologically manifested	11
Absent of clinical and morphological manifestations	46
Altogether	68

Clinically manifested cardiac lesions without morphological manifestations in 2 cases were discovered as a heart defect and accompanied with FMF ischemic heart disease. Morphologically manifested cardiac lesions without clinical manifestations as a cardiopathic amyloidosis with amyloid angiopathias in 9 cases were observed. Both clinically and morphologically manifested cardiac lesions in 11 cases were observed. Cardiac amyloidosis in investigated cases clinically was diagnosed as an acute or chronic ischemic heart disease, cardiomyopathy, valvular defects, degenerative changes and mixomatosis of heart valves.

Cardiac amyloidosis macroscopically was manifested with cardiomegaly, thickening of the heart valves, intraventricular septa and left ventricular wall. In 2 cases in myocardium the zones of infarction was found accompanied with diffuse microfocal car diosclerosis. In this cases atherosclerosis of coronary arteries were found.

Besides reactive changes and amyloidosis in myocardium in FMF, vascular affections of inflammatory genesis we had observed also. Coronary vasculitis was the one of the causes of acute ischemia and infarction of myocardium in FMF.

The literature data indicates on coexistence of vasculitis with FMF [1, 2].

According to the cadaver dissection material investigation data, progressive left ventricular heart failure prevailed in thanatogenesis leading to death in 2 cases. These cases clinically diagnosed as an acute myocardial infarction and morphologically large amyloid masses of the myocardium stroma with amyloid angiopathias were observed. The zone of infarction was not found macro- and microscopically. So called “pseudo infarctions” are characteristic clinically for cardiopathic amyloidosis in FMF.

Amyloid deposits in the endocardium, the stroma of the myocardium, as well as in vascular walls of all types microscopically determined (Fig. 1-4). Especially large amyloid deposits in small arterial and venous vessels partially in myocardium and epicardium were detected. In a few vessels of larger caliber amyloid deposition was determined in the adventitia and periadventitial tissue, sometimes accompanied with proliferation of adventitial cells. Amyloidosis is more expressed in arteriolar walls, with narrowing or completely closing of the vascular lumina.

In the stroma of myocardium amyloid masses displace the muscle tissue of the heart, leading to atrophy of cardiomyocytes. Different groups of muscle fibers were hypertrophied. In some areas dystrophic changes of cardiomyocytes were found. Around the amyloid mass

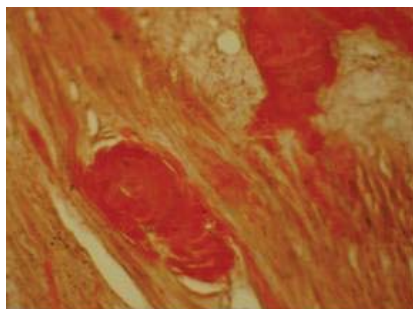


Figure 1 – Amyloid depositions in the stroma of myocardium, Congo red, x200

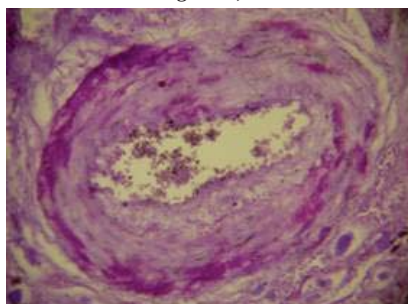


Figure 2 – Amyloid depositions of the myocardium arterial wall, methyl violet, x400.

diffuse proliferation of connective tissue with perifocal moderate lymphoplasmocytic infiltration revealed.

Conclusions

The investigation data observes that cardiac amyloidosis as a dominated morphological manifestation in FMF can leads to heart failure and death, which sometimes develops before renal failure and uremia. Amyloidosis of heart valves leads to their deformity and clinical-morphological picture of heart defect can perform. The large amyloid areas of myocardium leading to the heart insufficiency clinically were manifested with pseudo infarctions.

Summarize

Myocardium infarction develops in background of cardiac lesions in FMF, in which amyloid angiopathias and coronary vasculitis are main predisposing pathogenic factors.

Homozygotes for M694V may experience more severe disease and may be more likely to develop amyloidosis.

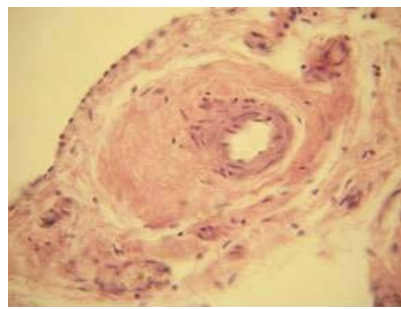


Figure 3 – Periadventitial amyloid depositions of small-caliber artery in myocardium, hematoxylin and eosin, x400

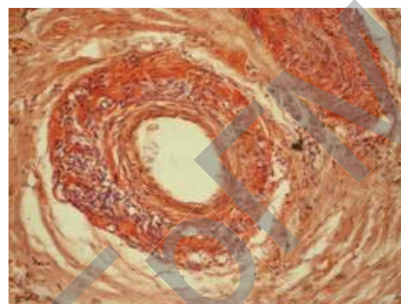


Figure 4 – Amyloid depositions of the arterial wall in myocardium, accompanied with proliferation of adventitial cells, Congo red, x400

References

1. Aksu, K. Coexistence of vasculitides with familial Mediterranean fever / K. Aksu, G. Keser. – Izmir: Rheumatol. Int., 2011. – 1263 p.
2. Balbir-Gurman, A. Vasculitis in siblings with familial Mediterranean fever / A. Balbir-Gurman, A. Nahir, Y. Braun-Moscovici. – Haifa: Clin. Rheumatol., 2007. – 1183 p.
3. Ben-Chetrit, E. Familial Mediterranean fever and renal amyloidosis-phenotype-genotype correlation, treatment and prognosis / E. Ben-Chetrit – Jerusalem: J. Nephrol., 2003. – 431 p.
4. Diffuse pulmonary amyloidosis that mimics interstitial lung disease in a patient with familial Mediterranean fever / H. Erdem [et al.]. – Ankara: J Clin Rheumatol. 2006. – 34 p.
5. Renal amyloidosis as a first manifestation of familial Mediterranean fever / K. Konstantopoulos [et al.]; – Athens: Scand. J. Rheumatol., 2000. – 129 p.
6. AA type renal amyloidosis secondary to FMF: a long-term follow-up in two patients / A. Kutlugun [et al.]; – Ankara: Clin. And Exper. Rheumatol., 2002. – 66 p.
7. Cardiac and intestinal amyloidosis in a renal transplant recipient with Familial Mediterranean fever / A. Yildiz [et al.]. – Istanbul: J. Nephrol., 2001. – 125p.

Кардиопатический амилоидоз как патогенетический фактор развития инфаркта миокарда при семейной средиземноморской лихорадке С.В. Амбарцумян

Ереванский государственный медицинский университет им. М.Гераци, Армения

Семейная Средиземноморская лихорадка (ССЛ) проявляется лихорадкой и кратковременными серозитами: перитонитом, плевритом, перикардитом и нередко осложняется вторичным амилоидозом. Проведен клинико-морфологический анализ 68 секционных наблюдений умерших с диагнозом ССЛ. Кардиопатический амилоидоз при ССЛ приводит к сердечной недостаточности. Макроскопически выявлена кардиомегалия, микроскопически амилоидоз выявлен в строме миокарда и в стенках сосудов. Сердечная недостаточность, связанная с кардиопатическим амилоидозом, иногда развивается до развития почечной недостаточности и уремии.

На фоне сердечных поражений ССЛ развивается инфаркт миокарда, при котором важным патогенетическим фактором являются амилоидные ангиопатии и коронарные васкулиты.

Наиболее тяжелое течение заболевания наблюдается у гомозиготов с М694V, у которых большая вероятность развития амилоидоза.

Ключевые слова: семейная Средиземноморская лихорадка, кардиопатический амилоидоз, морфология, инфаркт миокарда.

Поступила 25.04.2012