

Comparative Characteristics of Morphological Changes in Neurons of the Parietal Cortex of Rats with Anoxia of Ischemic and Respiratory Genesis

MA Feduto¹, N Ye Maksimovich², SM Zimatkin³, El Bon^{4*}, AI Grishchenko⁵, UA Bakush⁶ and DV Gaiko⁶

¹Assistant of the Department of Pathological Anatomy (forensic medicine), Republic of Belarus

²Doctor of Biological Sciences, professor, Head of the Department of Pathological Physiology named after D.A. Maslakov, Republic of Belarus

³Doctor of Biological Sciences, professor, Head of the Department of Histology, Cytology and Embryology, Republic of Belarus

⁴Candidate of Biological Sciences, Associate Professor of the Department of Pathological Physiology named after D.A. Maslakov, Associate Professor of Biological Sciences, Republic of Belarus

⁵4th year student of the Faculty of General Medicine, Republic of Belarus

⁶3rd year student of the Faculty of General Medicine, Republic of Belarus

Corresponding author: El Bon, Associate Professor of the Department of Pathological Physiology, Grodno State Medical University, Grodno, Republic of Belarus.

Received Date: December 19, 2022

Published Date: December 21, 2022

Annotation

Acute oxygen deficiency is the basis of a variety of pathological processes in many diseases and environmental factors. When studying the rat brain under conditions of its total ischemia and mechanical asphyxia, the presence of structural changes in both studied periods (after 30 and 60 minutes) was revealed: a decrease in the area and a change in shape (loss of sphericity and an increase in elongation) of cells, as well as a change in the degree of chromatophilia, which was manifested by a decrease in normochromic neurons with a simultaneous increase in hyperchromic shriveled neurons. At the same time, total cerebral ischemia led to more pronounced changes in the studied neurons of the parietal cortex, which was manifested by a more significant decrease in the area of neurons after 30 minutes of anoxia, while shape changes in the form of loss of sphericity and increased elongation were noted to a greater extent with mechanical asphyxia. These differences may be due to the preservation of cardiac activity during mechanical asphyxia for a short time.

Keywords: Anoxia; Neurons; Brain

Introduction

Acute oxygen deficiency is the basis of various pathological processes in many diseases and environmental factors [1-3]. In particular, oxygen deficiency in the brain can occur most often as a result of hemodynamic disorders (prolonged spasm, thrombosis, embolism of the vessel) or the influence of an external mechanical factor (mechanical asphyxia) [4,5]. Anoxia as an extreme degree

of oxygen starvation of brain cells, regardless of the causes, leads to its greatest damage. This is due to the complexity of the morphological structure and functions of the brain, as well as low tolerance to oxygen deficiency, which is determined by a high level of metabolism, lack of oxygen reserves and macroergic compounds [1-3]. The cerebral cortex deserves special attention, which is

associated with the extreme importance in the vital activity of the body and the severity of the consequences that develop when it is damaged [1,3,4,6].

To date, the pathomorphological, pathophysiological and clinical aspects of global anoxia have been covered in sufficient detail in the literature [2,4,7]. The peculiarity of anoxia of respiratory genesis, in contrast to anoxia of ischemic genesis, is that the heartbeat persists for a certain time. However, there is no blood oxygenation. In this regard, it is advisable to carry out a comparative analysis of neuronal changes in the brain with its total ischemia and mechanical asphyxia. The aim is to compare morphological changes in neurons of the parietal cortex of the rat brain during its anoxia caused by total ischemia and mechanical asphyxia.

Materials and Methods

The study was conducted on mongrel white rats (30 males, weight 240 ± 20 g), divided into 5 groups ($n=6$) in compliance with the requirements of Directive of the European Parliament and of the Council No. 2010/63/EU of 22.09.2010 on the protection of animals used for scientific purposes. The use of rats as experimental animals is due to the similarity of angioarchitectonics and cytoarchitectonics of the brain in rats and humans.

The Experiments were Performed on 2 Models of Brain Hypoxia

Total ischemia and mechanical asphyxia. The control group

consisted of falsely operated rats (group 1). Mechanical asphyxia was simulated by ligating the rat trachea for 30 minutes (group 2) and 60 minutes (group 3) [8]. Modeling of total cerebral ischemia was carried out by decapitation of rats with sampling 30 minutes (group 4) and 60 minutes (group 5) after decapitation [1]. The studies were carried out under intravenous anesthesia (sodium thiopental, 40 mg/kg). The brain was extracted and fixed in Carnoy's solution, after which frontal paraffin sections of the parietal cortex with a thickness of 7 microns were made and stained using the Nissl method [9]. The location of the parietal cortex was determined using a stereotactic atlas [10].

In each animal, 30 neurons of the fifth layer of the parietal cortex were studied to determine their size and shape [6,11]. Changes in the area and shape of neurons (form factor, elongation factor) were evaluated using the ImageWarp (Bitflow, USA). In histological preparations, various types of neurons were determined by the degree of staining of their cytoplasm (chromatophilia). The obtained quantitative continuous data were processed using methods of nonparametric statistics, licensed computer program Statistica 10.0 for Windows (StatSoft, Inc., USA). The data is presented in the form Me (LQ; UQ), where Me is the median, LQ is the boundary of the lower quartile; UQ is the boundary of the upper quartile. The differences between the indicators of the control and experimental groups were considered significant at $p<0,05$ (Mann-Whitney U-test) [12].

Result

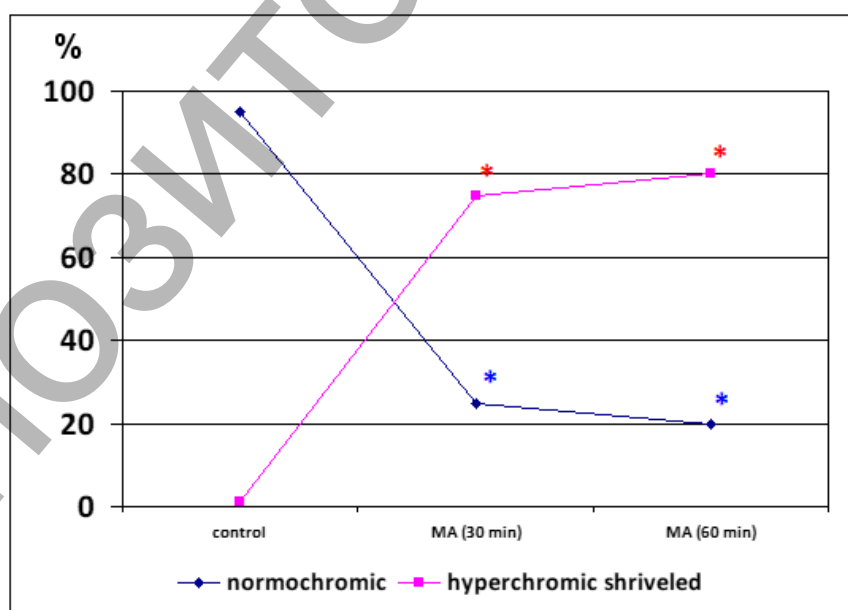


Figure 1: Dynamics of changes in the number of normochromic and hyperchromic shriveled neurons of the parietal cortex after 30 minutes and 60 minutes of mechanical asphyxia (MA).

***Note:** The differences are reliable compared to the control ($p<0,05$).

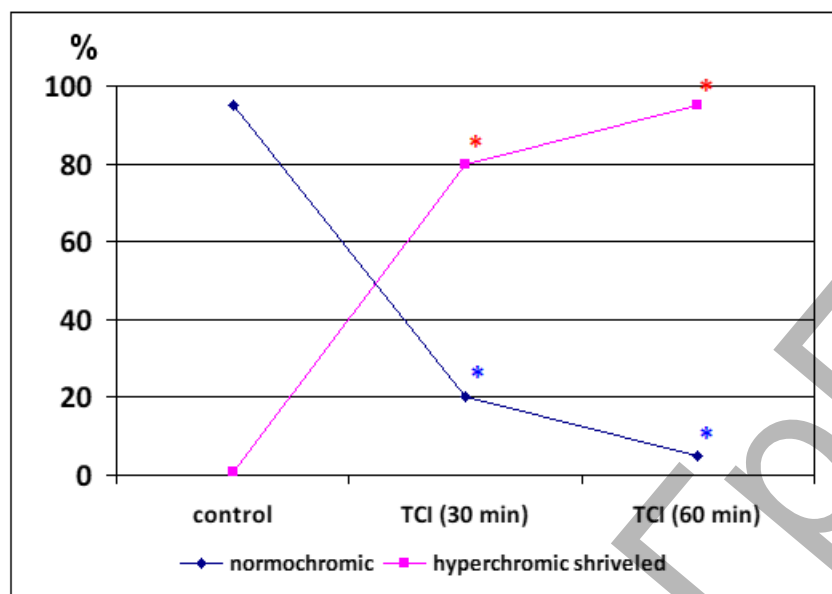


Figure 2: Dynamics of changes in the number of normochromic and hyperchromic shriveled neurons of the parietal cortex after 30 minutes and 60 minutes of total cerebral ischemia (TCI).

***Note:** The differences are reliable compared to the control ($p < 0.05$).

In the control group, up to 95% of the population of parietal cortex neurons were normochromic cells, and the remaining neurons were hypochromic (4%) and hyperchromic shriveled (1%) cells. In animals of the experimental groups, structural changes of neurons of the parietal cortex of the brain occurred, which manifested themselves in changes in the size, shape of neurons, and intensity of staining of their cytoplasm. Hyperchromic shriveled neurons – elongated and polygonal neurons with intensely colored cytoplasm – prevailed in both studied time intervals in total ischemia and mechanical asphyxia, about 75% in the group of rats with 30-minute mechanical asphyxia ($p < 0.05$) and about 80% in the group of rats with 60-minute mechanical asphyxia ($p < 0.05$), Fig. 1; about 80% – in the group of rats with 30 minute total ischemia ($p < 0.05$) and about 95% – in the group of rats with 60 minute total ischemia ($p < 0.05$), Fig. 2. Thus, in total ischemia and mechanical asphyxia, unidirectional changes in chromatophilia were noted equally ($p > 0.05$), which is manifested in a significant increase in hyperchromic shriveled neurons, which, as is known, are markers of acute oxygen deficiency of nervous tissue [1] (Figure 1,2).

There was no change in the area of neurons after 30 minutes of mechanical asphyxia ($p > 0.05$). But at the same time, a change in the shape of neurons was noted: the form factor decreased by 23% ($p < 0.05$), and the elongation factor increased by 70% ($p < 0.05$), which reflects the loss of sphericity and an increase in the elongation of the pericarions (Figure 3). In rats with total cerebral ischemia, by 30 minutes of the ischemic period, the area of neurons decreased by 74% ($p < 0.05$), while the form factor decreased by 33% ($p < 0.05$), and the elongation factor increased by 38% ($p < 0.05$), which reflects a lesser degree of loss of sphericity of neurons in unlike animals with mechanical asphyxia after 30 minutes. By 60 minutes of mechanical asphyxia, the area of neurons decreased by 35% ($p < 0.05$), while the form factor decreased by 31% ($p < 0.05$), and the elongation factor, on the contrary, increased by 75% ($p < 0.05$), which reflects the presence of changes in the shape of neurons that do not differ from those that they occurred with 30 minutes of mechanical asphyxia ($p > 0.05$). By 60 minutes of total cerebral ischemia, there was no aggravation of changes in the size and shape of neurons ($p > 0.05$) (Figure 3).

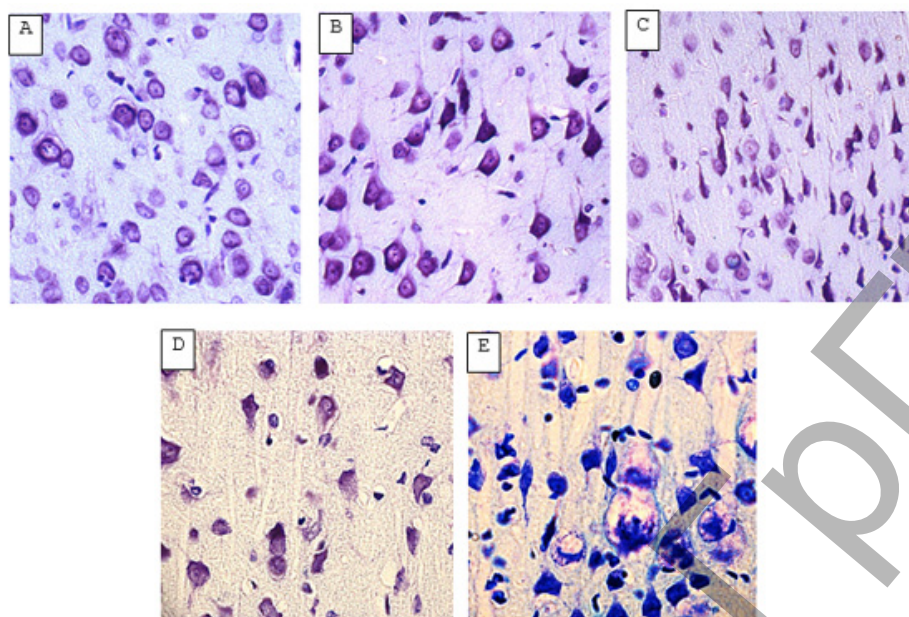


Figure 3: Neurons of the 5th layer of the parietal cortex of the rat brain. Digital microphotography. Stained by Nissl.

A – the control group (predominance of normochromic neurons); B – after 30 minutes of mechanical asphyxia (predominance of hyperchromic shrunken neurons); C – after 60 minutes of mechanical asphyxia (predominance of hyperchromic shrunken neurons); Magnification x 20. D – after 30 minutes of total ischemia (predominance of hyperchromic shrunken neurons); E – after 60 minutes of total ischemia (predominance of hyperchromic shrunken neurons). Magnification x 40.

So, the study of the effects of anoxia on neurons of the parietal cortex of the rat brain under conditions of its total ischemia and mechanical asphyxia revealed the presence of structural changes in both studied periods (after 30 and 60 minutes): reducing the area and changing the shape (loss of sphericity and increase in elongation) of cells, as well as a change in the degree of chromatophilia, which was manifested by a decrease in normochromic neurons with a simultaneous increase in hyperchromic shrunken neurons. At the same time, total cerebral ischemia led to more pronounced changes in the studied neurons of the parietal cortex, which was manifested by a more significant decrease in the area of neurons after 30 minutes of anoxia, while shape changes in the form of loss of sphericity and increased elongation were noted to a greater extent with mechanical asphyxia. These differences may be due to the preservation of cardiac activity during mechanical asphyxia for a short time.

Acknowledgment

None.

Conflict of Interest

No conflict of interest.

References

- Shin TH, Lee DY, Basith S, Manavalan B, Paik MJ, et al. (2020) Metabolome Changes in Cerebral Ischemia. *Cells*, 9(7): 1630.
- Koizumi S, Hirayama Y, Morizawa YM (2018) New roles of reactive astrocytes in the brain; an organizer of cerebral ischemia. *Neurochemistry International*, 107 p.
- Zhao Y, Zhang X, Chen X, Wei Y (2022) Neuronal injuries in cerebral infarction and ischemic stroke: From mechanisms to treatment (Review). *International Journal of Molecular Medicine*, 49(2): 15.
- Sylvestre DA, Otaki Y, Metherell AH, Bazinet RP, Slupsky CM, et al. (2022) Effects of hypercapnia / ischemia and dissection on the rat brain metabolome. *Neurochemistry International*.
- Sabeeha, Hasnain SE (2019) Forensic Epigenetic Analysis: The Path Ahead. *Medical Principles and Practice*, 301 p.
- Ma Z, Ma Y, Zhang N (2018) Development of brain-wide connectivity architecture in awake rats. *NeuroImage*, 176: 380-389.
- Robles RM, Dominguez Sala E, Martinez S, Geijo Barrientos E (2020) Layer 2/3 Pyramidal Neurons of the Mouse Granular Retrosplenial Cortex and Their Innervation by Cortico-Cortical Axons. *Frontiers in Neural Circuits*.
- Barkhuizen M, Kramer BW (2017) 25 years of research on global asphyxia in the immature rat brain. *Neuroscience & Biobehavioral Reviews*, 75: 166-182.
- Kayser G, Kayser K (2013) Quantitative pathology in virtual microscopy: history, applications, perspectives. *Acta Histochemica*, 115(6): 527-32.
- Paxinos G (1998) The Rat Brain in stereotaxic coordinates. C Watson, Academic Press Australia, 242 p.
- Paxinos G (2004) The rat nervous system. G Paxinos, Amsterdam – Boston – Heidelberg – London – New York – Oxford – Paris – San Diego – San Francisco – Singapore – Tokyo: Elsevier Acad Press, 1035 p.
- Brown BM, Newcombe RG (2009) Non-null semi-parametric inference for the Mann-Whitney measure. *Journal of Nonparametric Statistics*, 743 p.