

ESOPHAGEAL SQUAMOUS CELL PAPILLOMA.**CASE REPORT**¹S. S. Celi Simbaña, ²D. S. Andrade Mora, ³M. C. Vivar Dávila,⁴S. J. Loza Pavón, ⁵V. C. Naranjo Arboleda¹Center for Specialties Committee of the People I.E.S.S., Quito, Ecuador²Central University of Ecuador, Quito, Ecuador³Hospital General Latacunga I.E.S.S., Quito, Ecuador⁴General Teaching Hospital of Calderón, Quito, Ecuador⁵UTE University, Quito, Ecuador

Background. Esophageal squamous cell papillomas are rare epithelial lesions with malignant potential, diagnosed by upper gastrointestinal endoscopy. Their prevalence is from 0.01% to 0.43%.

Objective. Description of rare esophageal squamous papilloma diagnosed during upper gastrointestinal endoscopy.

Material and methods. A 38-year-old asymptomatic female patient underwent an upper gastrointestinal endoscopy. A growth described as an "esophageal polyp" was detected. The biopsy was performed and specimens were sent for histopathological study.

Results. The final diagnosis of esophageal squamous papilloma was made due to histopathological study. Because of the malignant potential of these lesions, once diagnosed, early treatment is essential to prevent progression to esophageal carcinoma.

Conclusions. Esophageal squamous papillomas are increasing in prevalence and have been shown to be potentially malignant. This argues the relevance of the problem and the need for widespread immunizations to control human papillomavirus infection.

Keywords: papillomas, squamous cell, papillomaviridae, case report.

ПЛОСКОКЛЕТОЧНАЯ ПАПИЛЛОМА ПИЩЕВОДА.**СЛУЧАЙ ИЗ ПРАКТИКИ**¹S. S. Celi Simbaña, ²D. S. Andrade Mora, ³M. C. Vivar Dávila,⁴S. J. Loza Pavón, ⁵V. C. Naranjo Arboleda¹Общественный центр комитета по специальностям Эквадорского института социального обеспечения, Кито, Эквадор²Центральный университет Эквадора, Эквадор³Больница общего профиля г. Латакунга Эквадорского института социального обеспечения, Кито, Эквадор⁴Клиническая больница г. Кальдерона, Кито, Эквадор⁵Университет УТЕ, Кито, Эквадор

Введение. Плоскоклеточные папилломы пищевода представляют собой редкие эпителиальные поражения со злокачественным потенциалом, диагностируемые с помощью эндоскопии верхних отделов желудочно-кишечного тракта. Их распространенность составляет от 0,01% до 0,43%.

Цель исследования – описание редкой плоскоклеточной папилломы пищевода, диагностированной при эндоскопии верхних отделов желудочно-кишечного тракта.

Материал и методы. Приведен случай из практики у пациентки 38 лет, у которой в ходе эндоскопии верхних отделов желудочно-кишечного тракта обнаружено новообразование, описанное как «полип пищевода». Взята биопсия и отправлена на гистопатологическое исследование.

Результаты. При гистологическом исследовании установлен окончательный диагноз плоскоклеточной папилломы пищевода. Из-за злокачественного потенциала этих поражений после постановки диагноза необходимо раннее лечение для предотвращения прогрессирования рака пищевода.

Выводы. Распространенность плоскоклеточных папиллом пищевода увеличивается, они потенциально злокачественны. Это доказывает актуальность проблемы и необходимость широкой иммунизации для борьбы с папилломавирусной инфекцией.

Ключевые слова: папилломы, плоскоклеточные клетки, папилломавирусы, клинический случай.

Corresponding author: Celi Simbaña Stalin Santiago, Center for Specialties Committee of the People I.E.S.S.; e-mail: ssantiago.celi19@gmail.com

Для цитирования: Плоскоклеточная папиллома пищевода. Случай из практики / S. S. Celi Simbaña, D. S. Andrade Mora, M. C. Vivar Dávila, S. J. Loza Pavón, V. C. Naranjo Arboleda // Гепатология и гастроэнтерология. 2022. Т. 6, № 2. С. 138-140. <https://doi.org/10.25298/2616-5546-2022-6-2-138-140>.

For citation: Celi Simbaña SS, Andrade Mora DS, Vivar Dávila MC, Loza Pavón SJ, Naranjo Arboleda VC. Esophageal squamous cell papilloma. Case report. Hepatology and Gastroenterology. 2022;6(2):138-140. <https://doi.org/10.25298/2616-5546-2022-6-2-138-140>.

Introduction

Esophageal squamous papillomas are rare, asymptomatic epithelial lesions with malignant potential. Characteristics that make them interesting findings for study. They are diagnosed by upper gastrointestinal endoscopy [1]. Its etiology is multifactorial, associated with human papillomavirus infection, chemical and/or mechanical irritation [2]. Its prevalence is 0.01% to 0.43%, however, Pantham et al (2017) reported an increase in squamous lesions of the esophagus in the last 14 years from 0.13% in 2000 to 0.57 % in 2013 [3,4].

In Ecuador, only two cases of squamous papillomas in the esophagus have been reported before this study [5].

Human papillomavirus infection has been related to the development of squamous cell carcinomas in the anogenital, oral, and laryngeal regions; the prevalence of dysplastic lesions of the hypopharynx ranges between 13% and 24% [6].

Most of these lesions are solitary (85%) small (between 2 and 6 mm), and located in the distal esophagus (70%) [7]. Diagnostic confirmation is made by biopsy and histopathological study, which shows thickened, acanthotic, squamous epithelium forming finger-like papillary projections with fibrovascular centers; without invasion of the submucosa [4].

Molecular studies suggest that the integration of the Human Papillomavirus with the host DNA is key in the malignant transformation of lesions, since it triggers the overexpression of viral proteins E6 and E7, early viral genetic by-products related to progression of malignancy [8, 9].

Objective

Description of rare esophageal squamous papilloma diagnosed during upper gastrointestinal endoscopy.

Materials and methods

A 38-year-old female patient, non-smoker, with Obesity grade 2 (BMI 32.4), asymptomatic, in pre-surgical evaluation for gastric sleeve type bariatric surgery.

An upper gastrointestinal endoscopy was performed, where a single elevated lesion was found in the distal 1/3 of the esophagus, reported as "Esophageal Polyp". A biopsy was taken and sent for histopathological study. The work was carried out after obtaining the informed consent of the patient.

Results

Figures 1-3 show the results of macroscopic and microscopic examination of the biopsy material.

Based on the results of the histopathological study diagnosis was reached: Histopathological image of squamous papilloma. Vienna classification 1 (Figure 2 and 3).

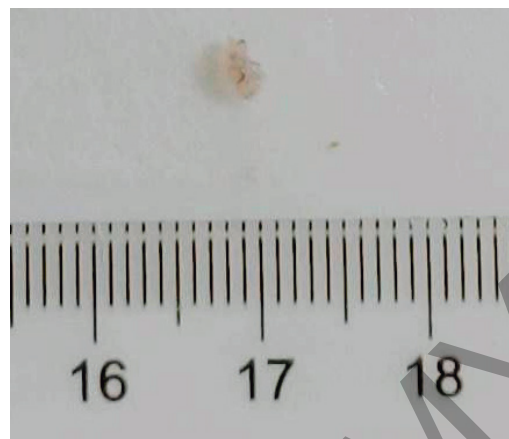

Figure 1. – Macroscopic view of biopsied tissue. Fragment of soft tissue, whitish, papillary in appearance, measuring 0.3 cm. Image courtesy of Pathologist: Dra. Vivar Cecilia

Рисунок 1. – Макроскопический вид биопсийной ткани. Фрагмент мягких тканей, беловатый, папиллярный на вид, размером 0,3 см. Изображение предоставлено патологоанатомом Dra. Vivar Cecilia

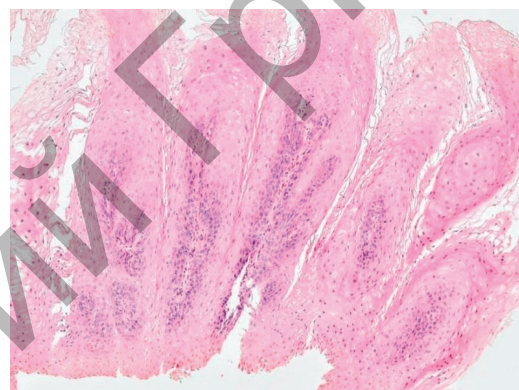


Figure 2. – Longitudinal Section of Biopsied Tissue. Indirect light microscope photography- Magnification: 20x. Stain: Hematoxylin-eosin. Papillary projections of squamous epithelium with fibrovascular centers. Image courtesy of Pathologist: Dra. Vivar Cecilia

Рисунок 2. – Продольный разрез биопсийной ткани. Фотосъемка под микроскопом с непрямым светом. Увеличение: 20х. Окраска: гематоксилин-эозин. Папиллярные выросты плоского эпителия с фиброваскулярными центрами. Изображение предоставлено патологоанатомом Dra. Vivar Cecilia

papillary leukoplakia), their therapeutic alternatives are: resection with biopsy, cauterization, radiofrequency ablation, mucosectomy for large lesions and esophagectomy if the presentation is extreme and does not respond to more conservative therapy [6]. In this case, the lesion was single and small, which corresponds to what is described in the literature. Most esophageal squamous papillomas are self-limited in immunocompetent people, once diagnosed, excision and histopathological study are recommended [10]. Regarding the etiology, since Syrjanen et al, the presence of human papillomavirus antigens in esophageal squamous papillomas was demonstrated, which is why it has been considered one of the most important etiological factors [2]. A weakness of the reported case is not having made the molecular diagnosis of the virus necessary for genotyping and, since it is a single lesion, there is no more tissue to carry out the study. Follow-up

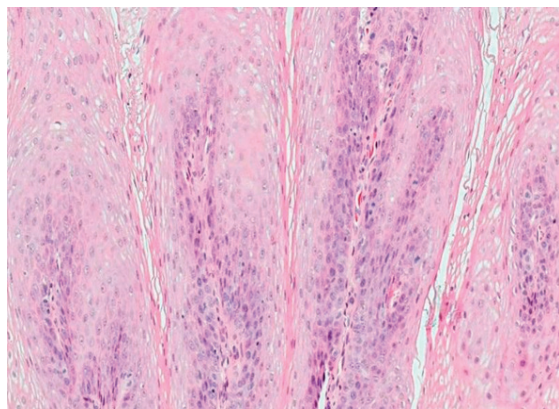


Figure 3. – Longitudinal section of biopsied tissue. Magnified View. Indirect light microscope photography - Magnification: 40×. Stain: Hematoxylin-eosin. Stratified squamous epithelium, without signs of dysplasia or nuclear atypia. Image courtesy of Pathologist: Dra. Vivar Cecilia

Рисунок 3. – Продольный срез биоптата. Увеличенный вид. Фото-съемка под микроскопом с непрямым светом. Увеличение: 40×. Окраска: гематоксилин-эозин. Многослойный плоский эпителий, без признаков дисплазии или ядерной атипии. Изображение предоставлено патологоанатомом Dra. Vivar Cecilia

Due to the malignant potential of these lesions and their macroscopic appearance similar to that of other less benign lesions such as (verrucous squamous cell carcinoma, granulation tissue or

with annual upper gastrointestinal endoscopy was suggested to the patient due to possible recurrence. HPV infection is acquired through direct contact with infected patients, so one of the best ways to reduce transmission rates is through vaccination and education [11]. There is consensus regarding the malignant potential of esophageal squamous papillomas. Therefore, once the diagnosis is made, histopathological and molecular studies and early treatment are essential to prevent progression to esophageal carcinoma [12]. We emphasize the importance of this incidental finding, given the scarcity of reports and the development of new minimally invasive therapeutic techniques, such as radiofrequency ablation and cryotherapy, which offer advantages over conventional treatments.

Conclusions

Esophageal squamous papillomas show a significant increase in prevalence in recent years. These lesions are potentially malignant, which argues their relevance and the need for widespread immunizations against human papillomavirus to control this pathology.

References

- Uhlenhopp DJ, Olson KM, Sunkara T. Squamous Cell Papilloma of the Esophagus: A Case Series Highlighting Endoscopic and Histologic Features. *Case Rep Gastrointest Med.* 2020;2020:7645926. doi: 10.1155/2020/7645926.
- Marshall DC, Kao DD, Bakst R, Sharma S, Ferrandino R, Rosenzweig K, Wisnivesky J, Sigel K. Prognostic role of human papilloma virus status in hypopharyngeal squamous cell carcinoma. *Laryngoscope Invest Otolaryngol.* 2020;5(5):860-867. doi: 10.1002/lto2.443.
- Yang L, Francois F, Pei Z. Molecular pathways: pathogenesis and clinical implications of microbiome alteration in esophagitis and Barrett esophagus. *Clin Cancer Res.* 2012;18(8):2138-2144. doi: 10.1158/1078-0432.CCR-11-0934.
- Chen SH, Wang JW, Li YM. Is alcohol consumption associated with gastroesophageal reflux disease? *J Zhejiang Univ Sci B.* 2010;11(6):423-428. doi: 10.1631/jzus.B1000013.
- Pantham G, Ganesan S, Einstadter D, Jin G, Weinberg A, Fass R. Assessment of the incidence of squamous cell papilloma of the esophagus and the presence of high-risk human papilloma virus. *Dis Esophagus.* 2017;30(1):1-5. doi: 10.1111/dote.12475.
- Savant D, Zhang Q, Yang Z. Squamous Neoplasia in the Esophagus. *Arch Pathol Lab Med.* 2021;145(5):554-561. doi: 10.5858/arpa.2020-0058-RA.
- Syrjänen S, Syrjänen K. HPV-Associated Benign Squamous Cell Papillomas in the Upper Aero-Digestive Tract and Their Malignant Potential. *Viruses.* 2021;13(8):1624. doi: 10.3390/v13081624.
- Zaravinos A. An updated overview of HPV-associated head and neck carcinomas. *Oncotarget.* 2014;5(12):3956-3969. doi: 10.18632/oncotarget.1934.
- Yim EK, Park JS. The role of HPV E6 and E7 oncoproteins in HPV-associated cervical carcinogenesis. *Cancer Res Treat.* 2005;37(6):319-324. doi: 10.4143/crt.2005.37.6.319.
- Bhat YM, Furth EE, Brensinger CM, Ginsberg GG. Endoscopic Resection with Ligation Using a Multi-Band Mucosectomy System in Barrett's Esophagus with High-Grade Dysplasia and Intramucosal Carcinoma. *Therap Adv Gastroenterol.* 2009;2(6):323-330. doi: 10.1177/1756283X09346794.
- Reynoso J, Davis RE, Daniels WW, Awad ZT, Gatalica Z, Filipi CJ. Esophageal papillomatosis complicated by squamous cell carcinoma in situ. *Dis Esophagus.* 2004;17(4):345-347. doi: 10.1111/j.1442-2050.2004.00438.x.
- Bohn OL, Navarro L, Saldivar J, Sanchez-Sosa S. Identificación de virus del papiloma humano en los papilomas escamosos esofágicos. *World J Gastroenterol.* 2008;14(46):7107-7111. doi: 10.3748/wjg.14.7107.

Conflict of interest. The authors declare no conflict of interest.

Financing. The study was performed without external funding.

Conformity with the principles of ethics. This work was carried out respecting all bioethical principles, maintaining the anonymity of the patient.

Information about authors: Celi Simbaña Stalin Santiago, Center for Specialties Committee of the People I.E.S.S.; e-mail: ssantiago.celi19@gmail.com; ORCID: 0000-0003-2091-9295

Andrade Mora Diego Sebastián, Central University of Ecuador; ORCID: 0000-0003-0669-1853

Vivar Dávila María Cecilia, Hospital General Latacunga I.E.S.S.; ORCID: 0000-0001-8905-9866

Loza Pavón Sebastian Javier, General Teaching Hospital of Calderón; ORCID: 0000-0002-8165-019X

Naranjo Arboleda Viviana Carolina, UTE University, ORCID: 0000-0002-5261-5088

Поступила: 07.10.2022

Принята к печати: 26.10.2022

Received: 07.10.2022

Accepted: 26.10.2022